

## SEED BODY FLUIDS



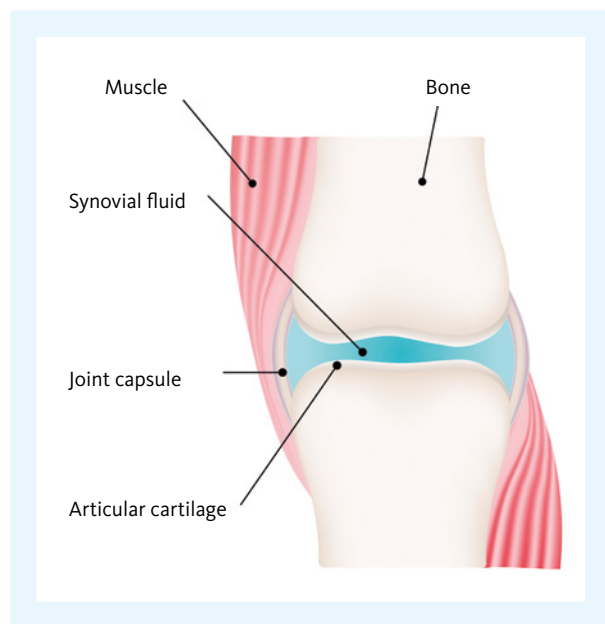
### Synovial fluid – part 1: main characteristics

This SEED article on synovial fluid consists of two parts. Part 1 focuses on the anatomy and composition of synovial fluid and it discusses indications for analysis. You will also receive some useful tips and tricks for specimen collection. Part 2 explains the laboratory analyses in more detail.

The word 'synovial' derives from the Latin word 'ovum' meaning 'egg' as normal synovial fluid resembles egg white. Synovial fluid, often also referred to as 'joint fluid', is located in all joints or diarthroses. Biochemically, synovial fluid is an ultrafiltrate of plasma across the synovial membrane enriched with various compounds produced by the synoviocytes. In physiological conditions, the biochemical composition of synovial fluid is similar to that of plasma. In pathological conditions, laboratory evaluation of synovial fluid provides information about the cause of the pathological condition affecting the joint. Indications include the evaluation of inflammation, infection, trauma and degenerative diseases of the joint.

#### **Anatomy and composition**

Synovial fluid is a viscous liquid found in the cavities of the movable joints or synovial joints (see Fig. 1). It is needed to maintain proper joint function by providing the structural support and supply of the necessary nutrients to the surrounding cartilage. Synovial fluid is mainly composed of two cell types, specialised macrophage-like synovial cells and synoviocytes (fibroblast-like cells), which are important in maintaining the internal joint homeostasis. The synoviocytes secrete a mucopolysaccharide containing hyaluronic acid and a small amount of protein into the fluid. The large hyaluronate molecules contribute to the noticeable viscosity of synovial fluid. The filtration is non-selective except for the exclusion of proteins of a high molecular weight. Therefore, the majority of the chemical constituents, although rarely of clinical significance, have concentrations similar to plasma values as shown in Table 1 [1].



**Fig. 1** Illustration of a synovial joint

**Table 1** Typical characteristics of synovial fluid

Physical appearance	
Total volume (e.g. adult knee joint)	<3.5 mL
Colour	Colourless or pale yellow
Clarity	Clear
Viscosity	High, forms 'strings' 4 to 6 cm long
Particle characteristics	
Red blood cell (RBC) count	<2,000 cells/ $\mu$ L
White blood cell (WBC) count	<200 cells/ $\mu$ L
WBC differential: Neutrophils	Not more than 25% of all white blood cells
Crystals	None present
Chemical components	
Glucose	Equivalent to plasma values
Uric acid	Equivalent to plasma values
Total protein	<3 g/dL

### Indications for synovial analysis

The differences in the appearance and cell content of abnormal synovial fluid could be related to different disease categories (Table 2); in particular, they help to distinguish between inflammatory and non-inflammatory forms of arthritis. Therefore, laboratory analysis of synovial fluid offers

some benefit since the results can be used to determine the pathological origin of arthritis. Analyses most frequently performed on synovial fluid are the WBC count and differential, Gram stain, culture, crystal examination and biochemical tests, such as glucose level determination.

There are two important reasons for synovial fluid analysis. The first is to identify joint infection by synovial fluid Gram stain and culture; the second is to diagnose crystal-induced arthritis by polarised light microscopy. Polarised light microscopy of synovial fluid allows the identification of urate (monosodium urate monohydrate) and pyrophosphate (calcium pyrophosphate dehydrate) crystals as a definite way of diagnosing gout or pseudogout. It has been shown that the detection of different types of crystals in synovial fluid may influence clinical diagnosis and treatment.

There have been many developments in the past decades, including the introduction of new synovial fluid biochemical markers, such as chondroitin 6-sulphate (C6S), chondroitin 4-sulphate (C4S), keratan sulfate (KS), tenascin-C (TN-C), and a resurgence of interest in synovial fluid cytology. On the other hand, the availability of other new diagnostic techniques (such as magnetic resonance imaging), associated with an increasing awareness of potential problems with routine joint aspiration and the handling of body fluids, has led to a general decrease in the numbers of this type of sample that arrive in the laboratory [2].

**Table 2** Classification and pathological significance of joint disorders [1]

Group classification	Pathological significance
1. Non-inflammatory	Degenerative joint disorders, osteoarthritis
2. Inflammatory	Immunologic disorders, rheumatoid arthritis, lupus erythematosus, scleroderma, polymyositis, ankylosing spondylitis, rheumatic fever, Lyme arthritis, crystal-induced gout and pseudogout
3. Septic	Microbial infection
4. Haemorrhagic	Traumatic injury, tumours, haemophilia, other coagulation disorders, anticoagulant overdose

### Specimen collection and handling

Synovial fluid is collected by needle aspiration called 'arthrocentesis'. The amount of fluid may vary and is related to the size of the joint and the extent of fluid build-up in the joint. As an example, the normal amount of fluid in the adult knee cavity is less than 3.5 mL, but can increase to more than 25 mL in inflammatory processes. Sometimes the collection may be difficult because only a few drops of fluid are obtained, but these can still be used for microscopy or culturing. The fluid from a diseased joint may contain fibrinogen, which could lead to spontaneous clotting. To avoid this situation, the fluid should be collected in a syringe that has been moistened with sodium heparin. When a sufficient amount of fluid has been collected it should be distributed into the following tubes, depending on the tests required [3]:

- A sterile heparinised tube for microbiology testing (e.g. Gram stain and culture)
- A sodium heparin or ethylenediaminetetraacetic acid (EDTA) tube for cell counting
- A sodium fluoride tube for glucose analysis
- A non-anticoagulated tube for other tests

Powdered anticoagulants should not be used because they may produce artefacts that could interfere with crystal analysis. The non-anticoagulated tube for other tests must be centrifuged and the supernatant decanted and collected in a fresh tube to prevent cellular elements from interfering with chemical and serologic analyses. The collected tubes should be transported to the laboratory without delay. If there is a significant delay in transport to be expected, the sample can be refrigerated. Ideally, all testing should be done as soon as possible to prevent the lysis of cells and possible changes in crystal morphology.

### Conclusion

- Synovial fluid is an important body fluid found in the cavities of synovial joints in order to reduce friction, enable shock absorption and ensure nutrient and waste transportation.
- The analysis of synovial fluid can be of major diagnostic value with acute arthritis, crystal arthropathy, septic arthritis and intercritical gout.

### References

- [1] **King Strasinger S et al.** (2008): *Urinalysis and Body Fluids. Fifth Edition.* © 2008 F. A. Davis Co.
- [2] **Swan A et al.** (2002): *The value of synovial fluid assays in the diagnosis of joint disease: a literature survey. Ann Rheum Dis.* 61:493–98.
- [3] **Mundt LA et al.** (2016): *Graff's Textbook of Urinalysis and Body Fluids. Third Edition.* © 2016 Wolters Kluwer.